

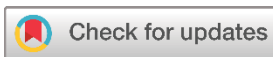Case Report

Bilateral Giant Pulmonary Hydatid Cysts in a Pediatric Patient: A Rare Case Report

Wirya N. Sabr¹, Azad Star Hattam¹, Karzan M. Hasan¹, Honar Othman Kareem¹, Harem K. Ahmed², Suhaib H. Kakamad³, Fahmi H. Kakamad^{4*}, Berun A. Abdalla⁵

1. Smart Health Tower, Madam Mitterrand Street, Sulaymaniyah, Kurdistan, Iraq
2. Department of Medicine, Shar Teaching Hospital, Sulaymaniyah, Kurdistan, Iraq
3. Collage of Medicine, Department of Immunology and Hematology, Kurdistan University of Medical Science, Sanandaj, Iran
4. College of Medicine, University of Sulaimani, Madam Mitterrand Street, Sulaymaniyah, Kurdistan, Iraq
5. Department of Biology, College of Education, University of Sulaimani, Madam Mitterrand Street, Sulaymaniyah, Kurdistan, Iraq

* **Corresponding author:** fahmi.hussein@univsul.edu.iq (F.H. Kakamad). Doctor City, Building 11, Apartment 50, Zip code: 46001, Sulaimani, Iraq



Keywords:
Echinococcus
Children
Lung
Hydatid cyst

Received: February 10, 2024
Revised: February 29, 2024
Accepted: March 12, 2024
First Published: March 20, 2024

Copyright: © 2024 Sabr et al. This is an open access article distributed under the terms of the Creative Commons Attribution License (<https://creativecommons.org/licenses/by/4.0/>), which permits unrestricted use, distribution, and reproduction in any medium, provided the original author and source are credited.

Citation: Sabr WN, Hattam AS, Hasan KM, Kareem HO, Ahmed HK, Kakamad SH et al. Bilateral Giant Pulmonary Hydatid Cysts in a Pediatric Patient: A Rare Case Report. Barw Medical Journal. 2024;2(2):63-67. <https://doi.org/10.58742/beb68v43>

Abstract

Introduction

Pulmonary hydatid cysts, resulting from the Echinococcus tapeworm larva, primarily affect the lungs. The global incidence is elevated in regions with prevalent livestock farming due to the ingestion of Echinococcus eggs. Bilateral involvement is an infrequent presentation, carrying inherent respiratory risks. Accurate and prompt diagnosis necessitates a comprehensive approach involving imaging studies and serological tests to uncover this parasitic affliction.

Case presentation

In a 15-year-old male from an underprivileged rural background, bilateral giant hydatid cysts manifested. The patient's exposure to this parasitic infection was linked to his rural setting and contact with pets. The case unfolded with respiratory symptoms, prompting an investigation that revealed substantial bilateral cystic lesions. Successful surgical intervention and diligent postoperative care resulted in a smooth and uncomplicated recovery for the patient.

Conclusion

While giant bilateral hydatid cyst cases are rare, their documentation provides invaluable insights into the understanding and management of this complex condition. The prognosis hinges on various factors, underlining the importance of a multidisciplinary post-surgical approach for optimal patient outcomes.

1. Introduction

A hydatid cyst, arising from the larval stage of the Echinococcus tapeworm, represents a parasitic infection manifesting particularly in the pulmonary form when cysts develop within the lungs [1]. The global incidence of this condition exhibits

variations, with higher prevalence noted in regions where livestock farming is prevalent [1,2]. The fundamental causative factor lies in the ingestion of Echinococcus eggs, typically

occurring through the consumption of contaminated food, water or direct contact with animals harboring the infection [1].

Several risk factors contribute to the likelihood of contracting pulmonary hydatid cysts, including proximity to dogs, involvement in livestock handling, and residing in areas endemic to the disease [1-3]. While bilateral involvement is a relatively uncommon manifestation, its occurrence introduces heightened risks due to potential complications, particularly the compromise of respiratory function [4,5].

The clinical presentation of pulmonary hydatid cysts is diverse, encompassing symptoms such as cough, chest pain, and various respiratory manifestations [1,2]. Timely and accurate diagnosis is crucial and typically involves a comprehensive approach. Imaging studies, such as chest X-rays or CT scans, play a pivotal role in visualizing cystic structures [6,7]. Serological tests aid in confirming the presence of the *Echinococcus* infection, complementing the clinical evaluation for a comprehensive diagnostic assessment [8,9].

The significance of reporting a case involving bilateral giant pulmonary hydatid cysts cannot be overstated. Such cases are exceedingly rare and underscore the importance of understanding the potential complications associated with this unique presentation. Emphasizing the urgency of early diagnosis and intervention is imperative, given the heightened risk of respiratory compromise in bilateral cases.

2. Case Presentation

2.1. Patient information

A 15-year-old male patient reported a gradual emergence of dyspnea and cough persisting for a month. His past medical and surgical history was unremarkable. Coming from an underprivileged family in a rural setting, he had been exposed to pets.

2.2. Clinical findings

A physical examination revealed decreased bilateral air entry, although vital signs remained normal.

2.4. Therapeutic intervention

A chest x-ray depicted bilateral giant round homogeneous opacities in both the upper and middle zones of the right lung and the middle and lower zones of the left lung (Figure 1). A subsequent chest CT scan revealed two homogeneous cystic lesions, exhibiting peripheral enhancement and occupying the majority of both hemithoraces. These lesions measured 16x14 cm on the right and 14x12 cm on the left, indicative of bilateral giant hydatid cysts (Figure 2). The patient's complete blood count highlighted eosinophilia, with an eosinophilic count of 700 cells/microliter. Both abdominal ultrasound and brain CT scan results were normal.

The patient received a preoperative dose of 400 mg intravenous ciprofloxacin, as per the hospital's protocol.

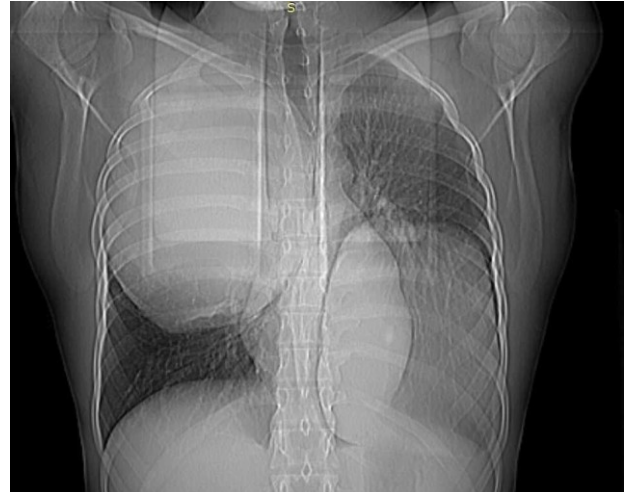

Figure 1: Plane chest X-ray (posteroanterior view) showing bilateral large homogenous well-defined opacity.

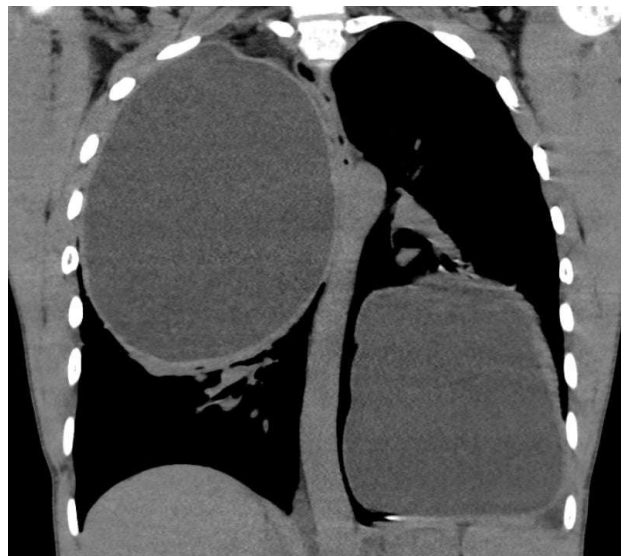

Figure 2: computed tomography scan of the chest (coronal view) showing two giant hydatid cysts on both sides of the chest.

The surgery was performed under general anesthesia. Positioned laterally on the left with a single lumen endotracheal intubation, a 5 cm utility incision was made in the fifth intercostal space, located in the posterior axillary line. Additionally, a 1 cm incision was made in the sixth intercostal space, anterior axillary line, to accommodate the camera. For the right-side cyst, a controlled evacuation was executed post-isolation with packs soaked in hypertonic saline. The germinal membrane including the daughter cysts and pericysts was removed, the fistulae were closed, and the residual cavity was rinsed with hypertonic saline and closed by 2-0 vicryl (Figure 3). A chest drain was inserted. The same procedure was repeated for the left-side cyst within the same session (Figure 4).

The patient's recovery was smooth and uncomplicated. Postoperative care included a prescription of oral albendazole 400 mg twice daily and pain management with paracetamol 1 gm thrice daily, ketorolac 30 mg thrice daily, and pethidine 50 mg

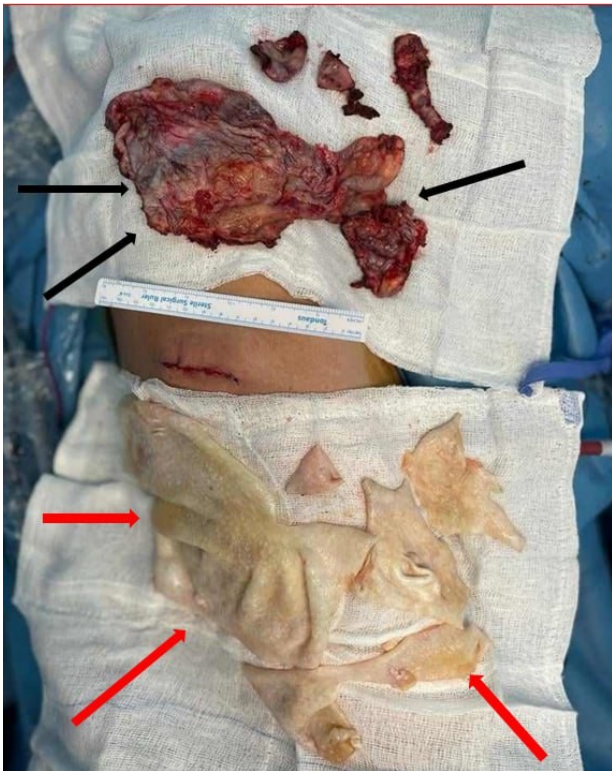


Figure 3: post-operative findings of the right side showing germinal layers (red arrows) and pericyst (black arrows).

as needed subcutaneously. Intravenous ciprofloxacin 400 mg was administered twice daily for 48 hours post-surgery. The left-side chest drain was removed on the third postoperative day, and the right-side drain on the fourth. The patient was discharged in good health on the fifth postoperative day.

2.4. Follow-up

At a follow-up visit six weeks post-surgery, the patient displayed no significant respiratory issues. He was instructed to continue taking albendazole for six months and to regularly monitor his liver enzymes.

4. Discussion

Pulmonary hydatid cysts pose a significant threat to health, yielding a spectrum of symptoms ranging from respiratory distress, persistent cough, and chest pain to potentially life-threatening complications, including cyst rupture, infection, or anaphylaxis [1,2]. The geographical prevalence of the disease is notably higher in regions where livestock farming is commonplace, such as parts of Asia, Africa, South America, the Middle East, and certain areas in Europe [10,11].

The diagnostic landscape of pulmonary hydatid cysts is marked by challenges attributed to the nonspecific nature of symptoms and the gradual progression of the disease [1,2,9]. Clinical suspicion arises particularly in individuals hailing from endemic regions with a history of animal contact [12]. Instrumental in the

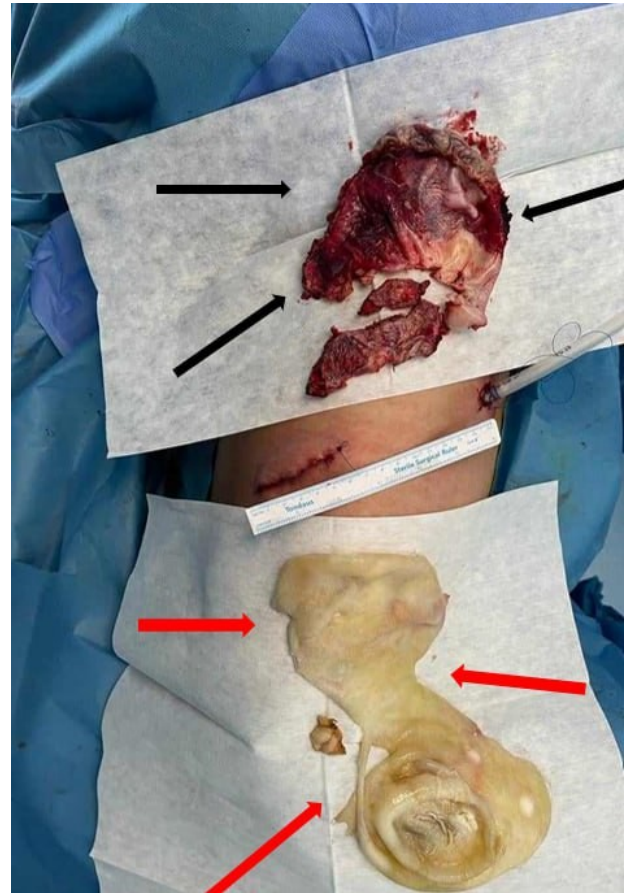


Figure 4: post-operative findings of the left side showing germinal layers (red arrows) and pericyst (black arrows).

diagnostic process is imaging studies, with chest X-rays and CT scans playing a pivotal role in visualizing the characteristic cystic structures [6,7,13,14].

Guidelines for managing pulmonary hydatid cysts primarily advocate for surgical intervention, as endorsed by the World Health Organization (WHO) [15-19]. The overarching objective of surgery is to excise the cyst intact, thereby mitigating the risk of complications [20,21]. Complementary to surgical measures, medical treatment involving anthelmintic drugs like albendazole assumes the role of adjunctive therapy, aiding in reducing the likelihood of recurrence and addressing any residual cystic structures [22,23].

Despite the potential rarity of giant bilateral hydatid cyst cases in the existing literature, the importance of disseminating such cases cannot be overstated. Reports of these unique presentations contribute invaluable insights into evolving management strategies and outcomes, fostering a deeper understanding of this complex condition.

Prognosis and the success of surgical interventions hinge on multifactorial considerations, including the size and location of the cysts, the overall health of the patient, and the surgical approach adopted. When executed with precision, surgery often culminates in a favorable outcome, alleviating symptoms and improving the patient's quality of life [13,21]. However, the presence of complications, such as cyst rupture during surgical

procedures, introduces nuances that may impact the overall prognosis [24-26].

Post-surgical medical treatment assumes a crucial role in preventing recurrence and managing residual disease. Regular and comprehensive follow-up, encompassing imaging studies and clinical assessments, becomes imperative to monitor for any signs of recurrence or potential complications [9,22,23].

5. Conclusion

The successful management of pulmonary hydatid cysts necessitates a collaborative and multidisciplinary approach, seamlessly integrating surgical expertise with ongoing medical treatment to optimize patient outcomes.

Declarations

Conflicts of interest: The authors have no conflicts of interest to disclose.

Ethical approval: Not applicable.

Patient consent (participation and publication): Written informed consent was obtained from the parent for participation in the present study and the publication of the present case report and any accompanying images.

Funding: The present study received no financial support.

Acknowledgments: None to be declared.

Authors' contributions: FHK was a major contributor to the conception of the study, as well as to the literature search for related studies. SHK, BAA, and HKA were involved in the literature review, the writing of the manuscript, and the processing of the figures. WNS, ASH, KMH, and HOK were involved in the literature review, the design of the study, and the critical revision of the manuscript. FHK and BAA Confirmation of the authenticity of all the raw data. All authors approved the final version of the manuscript.

Use of AI: AI was not used in the drafting of the manuscript, the production of graphical elements, or the collection and analysis of data.

Data availability statement: Not applicable.

References

- Rawat S, Kumar R, Raja J, Singh RS, Thingnam SKS. Pulmonary hydatid cyst: Review of literature. *J Fam Med Prim care*. 2019 ;8(9):2774–8. doi:N/A
- Morar R, Feldman C. Pulmonary echinococcosis. *Eur Respir J*. 2003;21(6):1069 LP – 1077. doi:10.1183/09031936.03.00108403
- Sarkar M, Pathania R, Jhobta A, Thakur BR, Chopra R. Cystic pulmonary hydatidosis. *Lung India*. 2016;33(2):179–91. doi:10.4103/0970-2113.177449
- Daghfous H, Zendah I, Kahloul O, Tritar-Cherif F. [Pleural complications of pulmonary hydatid disease]. *Tunis Med*. 2014;92(1):6–11. doi:N/A
- Salimi M, Assar S, Mohamadzadeh D, Kanjorpor A. Acute respiratory distress syndrome after spontaneous rupture of a large pulmonary hydatid cyst in a 17-year-old male: A case report. Vol. 11, *Clinical case reports*. England; 2023. p. e7194. doi:10.1002/ccr3.7194
- Durhan G, Tan AA, Düzgün SA, Akkaya S, Anyürek OM. Radiological manifestations of thoracic hydatid cysts: pulmonary and extrapulmonary findings. *Insights Imaging*. 2020;11(1):116. doi:10.1186/s13244-020-00916-0
- Choh NA, Parry AH, Wani AH, Feroz I, Bhat MH, Shaheen FA. The spectrum of imaging findings in pulmonary hydatid disease and the additive value of T2-weighted magnetic resonance imaging in its diagnosis. *Polish J Radiol*. 2021;86:e53–63. doi:10.5114/pjr.2021.103237
- Tamarozzi F, Silva R, Fittipaldo VA, Buonfrate D, Gottstein B, Siles-Lucas M. Serology for the diagnosis of human hepatic cystic echinococcosis and its relation with cyst staging: A systematic review of the literature with meta-analysis. *PLoS Negl Trop Dis*. 2021;15(4):e0009370. doi:10.1371/journal.pntd.0009370
- Brunetti E, Kern P, Vuitton DA. Expert consensus for the diagnosis and treatment of cystic and alveolar echinococcosis in humans. *Acta Trop*. 2010;114(1):1–16. doi:10.1016/j.actatropica.2009.11.001
- Tamarozzi F, Legnardi M, Fittipaldo A, Drigo M, Cassini R. Epidemiological distribution of *Echinococcus granulosus* s.l. infection in human and domestic animal hosts in European Mediterranean and Balkan countries: A systematic review. *PLoS Negl Trop Dis*. 2020;14(8):e0008519. doi:10.1371/journal.pntd.0008519
- Karshima SN, Ahmed MI, Adamu NB, Magaji AA, Zakariah M, Mohammed K. Africa-wide meta-analysis on the prevalence and distribution of human cystic echinococcosis and canine *Echinococcus granulosus* infections. *Parasit Vectors*. 2022;15(1):357. doi:10.1186/s13071-022-05474-6
- Saghebi SR, Moniri A, Marjani M, Daneshvar Kakhaki A. A Potentially Fatal Error in Diagnosis of a Pulmonary Hydatid Cyst. *Arch Clin Infect Dis*. 2018;13(4):e57296. <https://brieflands.com/articles/archcid-57296.html>
- Arinc S, Kosif A, Ertugrul M, Arpag H, Alpay L, Ünal Ö, et al. Evaluation of pulmonary hydatid cyst cases. *Int J Surg*. 2009;7(3):192–5. doi:10.1016/j.ijsu.2008.11.003
- Abbasi B, Akhavan R, Ghamari Khameneh A, Darban Hosseini Amirkhiz G, Rezaei-Dalouei H, Tayebi S, et al. Computed tomography and magnetic resonance imaging of hydatid disease: A pictorial review of uncommon imaging presentations. *Heliyon*. 2021;7(5):e07086. doi:10.1016/j.heliyon.2021.e07086
- Celik M, Halezeroglu S, Senol C, Keles M, Yalcin Z, Urek S, et al. Video-assisted thoracoscopic surgery: experience with 341 cases. *Eur J Cardio-Thoracic Surg*. 1998;14(2):113–6. doi:10.1016/S1010-7940(98)00167-5
- Ahmed SK, Essa RA, Bapir DH. Uniportal Video-assisted Thoracoscopic Surgery (u-VATS) for Management of pulmonary hydatid cyst: A systematic review. Vol. 75, *Annals of medicine and surgery* (2012). Department of Emergency, Rania Teaching Hospital, Rania, Sulaimani, Kurdistan-region, Iraq; 2022. p. 103474. doi:10.1016/j.amsu.2022.103474
- Ma J, Wang X, Mamatimin X, Ahan N, Chen K, Peng C, et al. Therapeutic evaluation of video-assisted thoracoscopic surgery versus open thoracotomy for pediatric pulmonary hydatid disease. *J Cardiothorac Surg*. 2016;11(1):129. doi:10.1186/s13019-016-0525-9
- Abbas N, Zaher Addeen S, Abbas F, Al Saadi T, Hanafi I, Alkhatib M, et al. Video-assisted Thoracoscopic Surgery (VATS) with mini-thoracotomy for the management of pulmonary hydatid cysts. *J Cardiothorac Surg*. 2018;13(1):35. doi:10.1186/s13019-018-0716-7
- Doğan R, Yüksel M, Cetin G, Süzer K, Alp M, Kaya S, et al. Surgical treatment of hydatid cysts of the lung: report on 1055 patients. *Thorax*. 1989;44(3):192–9. doi:10.1136/thx.44.3.192
- Salih, A. M., Ahmed, D. M., Kakamad, F. H., Essa, R. A., Hunar, A., Ali, H. M. . Primary chest wall Hydatid cyst: Review of literature with report of a new case. *International Journal of Surgery Case Reports*. 2021;6: 41, 404-406. doi:10.1016/j.ijscr.2017.10.051
- Salih, A. M., Kakamad, F., & Rauf, G. M. Isolated hydatid cyst of the diaphragm, a case report. *International Journal of Surgery Case Reports*. 2015; 29, 130-132. doi:10.1016/j.ijscr.2016.10.071
- Aydin Y, Ulas AB, Ince I, Kalin A, Can FK, Gundogdu B, et al. Evaluation of albendazole efficiency and complications in patients with pulmonary hydatid cyst. *Interact Cardiovasc Thorac Surg*. 2022;34(2):245–9. doi:10.1093/icvts/ivab259
- Usluer O, Kaya SO, Samancilar O, Ceylan KC, Gursoy S. The effect of preoperative albendazole treatment on the cuticular membranes of pulmonary hydatid cysts: should it be administered preoperatively? *Kardiocirurgia i torakocirurgia Pol = Polish J cardio-thoracic Surg*. 2014;11(1):26–9. doi:10.5114/kiip.2014.41926

24. Karimi M, Rostami A, Spotin A, Rouhani S. Ruptured pulmonary hydatid cyst: a case report. *J Parasit Dis Off organ Indian Soc Parasitol.* 2017;41(3):899–902. [doi:10.1007/s12639-017-0880-z](https://doi.org/10.1007/s12639-017-0880-z)
25. Salih, A. M., Kakamad, F. H., Salih, R. Q., Rahim, H. M., Habibullah, I. J., Hassan, H. A. et al. Hydatid cyst of the thigh: A case report with literature review. *International Journal of Surgery Case Reports.* 2017; 51, 8-10. [doi:10.1016/j.ijscr.2018.08.007](https://doi.org/10.1016/j.ijscr.2018.08.007)
26. Shameem M, Akhtar J, Bhargava R, Ahmed Z, Khan NA, Baneen U. Ruptured Pulmonary Hydatid Cyst with Anaphylactic Shock and Pneumothorax. *Respir Care.* 2011;56(6):863 LP – 865. [doi:10.4187/respcare.00821](https://doi.org/10.4187/respcare.00821)