

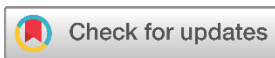## Systematic Review

# Hydatid Cysts of the Bladder: A Systematic Review of the Literature

Ranj A. Hasan<sup>1\*</sup>, Fakher Abdullah<sup>2</sup>, Bokan Talib Saeed<sup>1</sup>

1. University Clinic of Urology, Klinikum Herford, Germany
2. Kscien Organization for Scientific Research (Europe office), Verboomstraat 175b, 3082 jj Rotterdam, Netherlands.

\* Corresponding author: [anj.hasan@klinikum-herford.de](mailto:anj.hasan@klinikum-herford.de) (R.A. Hasan). Auf dem Dudel 53, 32049 Herford, Germany



**Keywords:**  
Urinary bladder  
Hydatid cyst  
Operation  
Echinococcus

Received: July 25, 2023  
Revised: August 10, 2023  
Accepted: August 17, 2023  
First Published: August 23, 2023

Copyright: © 2023 Hasan et al. This is an open access article distributed under the terms of the Creative Commons Attribution License (<https://creativecommons.org/licenses/by/4.0/>), which permits unrestricted use, distribution, and reproduction in any medium, provided the original author and source are credited.

Citation: Hasan RA, Abdullah F, Saeed BT. Hydatid Cysts of the Bladder: A Systematic Review of the Literature. Barw Medical Journal. 2023;1(3):22-25. <https://doi.org/10.58742/bmj.v1i2.46>

## Abstract

### Introduction

Hydatid cysts mainly involve the liver and lungs, other areas may rarely be affected by the disease. Urinary bladder hydatid cysts are extremely rare. The aim of this study is to review hydatid cysts of the bladder.

### Methods

We conducted a systematic literature search using various PubMed, Scopus, Web of Science, and Google Scholar were explored to identify papers that discussed hydatid cysts in the urinary bladder. Studies with incomplete reports or insufficient data were excluded, as were those published in predatory journals. The studies were identified through both electronic and manual searches. Sociodemographic and clinical data were extracted and discussed.

### Results

The study included 122 articles, 6 studies were for full assessment and review. Seven cases were found in the papers, 4 patients (57%) were female, and 3 patients (43%) were male. Surgical intervention was the mainstay of the management without significant complications.

### Conclusion

Bladder hydatid cyst is a rare condition with few reported cases. It presents a diagnostic challenge to the physician. Surgical intervention is the best management option.

## 1. Introduction

Hydatid cyst is a fluid-filled sac that forms in the body as a result of the larval stage of *Echinococcus granulosus* infecting humans or animals. The cyst is formed by the growth of the parasite within an organ, leading to the development of a thick outer wall and an inner fluid-filled cavity [1,2]. The life cycle of *Echinococcus granulosus* involves two hosts: a definitive host (usually dogs or other canids) and an intermediate host (usually herbivores like sheep, goats, or cattle). The adult tapeworm lives in the small intestine of the definitive host, where it produces eggs that are excreted in the feces [3,4]. If these eggs are ingested by an intermediate host, they hatch in the small intestine and penetrate the intestinal wall, entering the

bloodstream. From there, the larvae can be carried to various organs, most commonly the liver and lungs, through the circulatory system. Once the larvae reach an organ, they develop into hydatid cysts. The cysts gradually enlarge over several years, and the fluid-filled cavity inside them contains numerous daughter cysts. These daughter cysts contain even smaller cysts, known as protoscolices, which can develop into adult tapeworms if ingested by the definitive host, completing the life cycle [5,6].

Hydatid cysts are most prevalent in areas where there is close contact between humans and infected animals, particularly in

rural agricultural communities. The infection occurs worldwide but is more common in certain regions, including parts of South America, Africa, the Mediterranean, the Middle East, Central Asia, and Australia [7,8]. Occupations involving close contact with livestock, such as farmers, shepherds, and abattoir workers, are at higher risk of contracting hydatid cysts. Additionally, dogs that have access to livestock or ingest offal from infected animals can act as a source of infection. The disease is more common in children and young adults due to their increased likelihood of close contact with animals and a higher susceptibility to infection [9,10].

Hydatid cysts typically affect the liver and lungs. However, in rare instances, these cysts can manifest in unconventional locations throughout the body. These occurrences pose unique challenges in diagnosis and treatment due to their atypical presentation and potential complications [11,12]. The aim of this study is to revise the occurrence of hydatid cysts in the urinary bladder with a brief highlight on the presentation and management.

## 2. Methods

### 2.1. Study protocol

The present systematic review adhered to the guidelines outlined in the Preferred Reporting Items for Systematic Reviews and Meta-Analyses (PRISMA).

### 2.2. Literature search

Until July 3, 2023, we conducted searches in various databases, including PubMed, Scopus, Web of Science, and Google Scholar, to identify papers that discussed hydatid cysts in the urinary bladder. The search terms used were "hydatid cysts of the urinary bladder," "hydatid cyst of the urinary bladder," "urinary bladder hydatid cyst," and "urinary bladder hydatid cyst." Additionally, we referred to the references cited in the included studies to augment our data collection process.

### 2.3. Eligibility criteria

The study's inclusion criteria targeted case reports and case series focusing on hydatid cysts in the urinary bladder. This also encompassed studies describing hydatid cysts occurring simultaneously in other parts of the body. Studies with incomplete reports or insufficient data were excluded. Referenced articles have been assessed for qualification and eligibility based on Kscien's list [13].

### 2.4. Study selection process

The studies were identified through both electronic and manual searches, and any duplicate entries were removed. Three authors independently reviewed the titles and abstracts of the publications to exclude irrelevant ones. After the initial screening, the authors evaluated the full texts of the remaining publications using the predefined inclusion and exclusion criteria.

### 2.5. Data items

Data extraction was performed using Microsoft Office Excel. From each study, the following information was collected: (1) fundamental details about the articles, including title, first author's name, study design, country, and publication date; (2) details about the reported cases, such as the number of cases, age, gender, and past medical history; and (3) information regarding the presenting symptoms.

## 3. Results

In the initial database searches, 122 articles were identified (plus one article from the references). After removing 90 duplicates, there were 33 unique articles left. Reviewing the titles and abstracts led to the exclusion of 20 irrelevant studies. During the

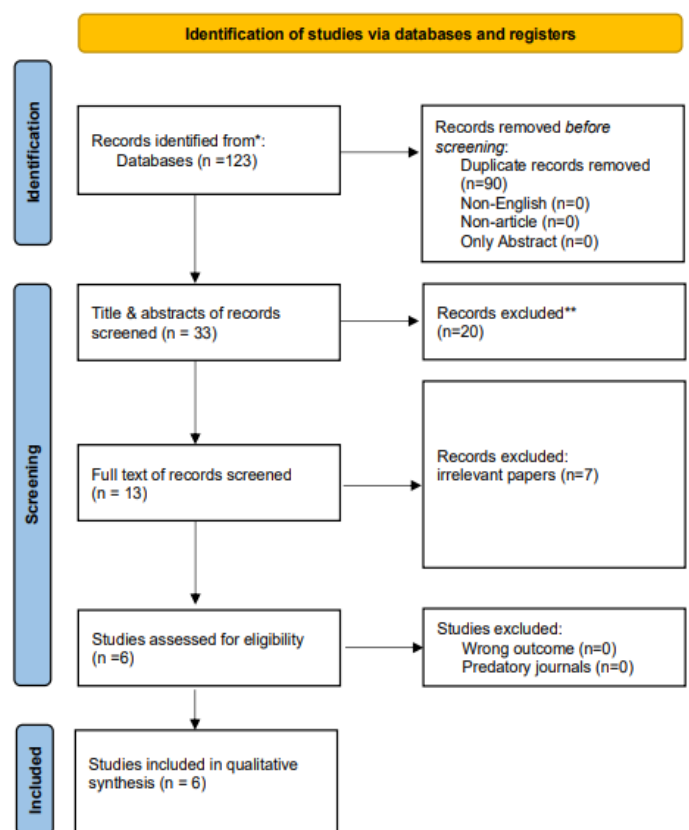


Figure 2. Study selection PRISMA flow chart.

full-text screening, 7 more irrelevant papers were eliminated. Ultimately, 6 papers were selected for further assessment (figure1). Seven cases were found in the six papers, 4 patients (57%) were female, and 3 patients (43%) were male. Surgical intervention was the mainstay of the management without significant complications (table 1).

## 4. Discussion

**Table 1.** Full description of the cases and corresponding recommendations.

Author/Reference	Country/Year	No. of patients	Age/ Gender	Signs and symptoms/Duration	Other involved regions, History of hydatid disease	Management
Arif et al. [14]	Iraq/2018	1	35/male	Lower abdominal pain and tenderness with two times vomiting/3 months	None	Surgical Excision
Ganie et al. [15]	Indain/2013	1	48/male	Lower abdominal pain, urgency, feeling of incomplete urination/2 years	Hydatid cyst of the liver 10 years ago, operated	Surgical Excision
Kanagal et al. [16]	Indian/2010	1	16/female	Recurrent episode of abdominal pain and tenderness with a recurrent episode of urinary tract infection/4 months	None	Surgical Excision +Albendazole
Malakzai et al. [17]	Afghanistan/2023	1	43/male	Sensation of a mass in the lower abdomen and urine retention/not mentioned	None	Endoscopic resection + levofloxacin and Albendazole
Harlan et al. [18]	Germany/1894	1	51/female	Pain in the right hypochondriac region with dyspnoea and chills, lump in the right hypochondrium, slight jaundice/2 days	History of hydatid cysts of the liver, pleura, omentum, mesentery and peritoneum.	Surgical Excision
			50/female	Severe strangury, palpable tense cystic mass in suprapubic region and in right loin, massive hematuria, grape-like clusters in the urine which contain Scoleces identified as <i>Echinococcus granulosus</i> infestation/not mentioned.	Hydatid cyst of the liver, operated before 30 years	Conservative-Intracystic instillation of 20% saline for 30 minutes daily followed by bladder wash with sterile water for a week +blood transfusion
Vaidyanath et al [19]	USA/2012	2	10/female	Strangury, hematuria passage of grape-like clusters in the urine, palpable suprapubic cystic mass/2 days	None	Conservative-Intravesical hypertonic saline (20%) followed by bladder irrigation with sterile water after micturition daily for 2 weeks

Hydatid cysts can reach other organs apart from the lung and liver through a process known as "hematogenous spread." The hematogenous spread refers to the dissemination of the parasite's bones, and even soft tissues [3,20]. Hydatid cysts of the urinary bladder could be less commonly

eggs or cyst contents through the bloodstream to distant organs. When the hydatid cyst in the primary site, such as the liver or lung, ruptures, it releases protoscolices and hydatid fluid containing the *Echinococcus* larvae [2,20].

These larvae can enter the bloodstream, and from there, they can be transported to various organs throughout the body. As the blood circulates, the larvae may get trapped in small blood vessels of other organs, where they can develop into new hydatid cysts over time. The most common organs affected by hematogenous spread include the brain, heart, spleen, kidneys, explained by the hematogenous spread as the bladder is less vascularized in comparison to other organs like brain, kidneys and heart. Hematogenous dissemination of hydatid cysts is less common than the direct extension of the cysts into neighboring tissues or organs. Nonetheless, it is still an important consideration in the clinical management of echinococcosis, and

it highlights the potential for complications and widespread involvement of different organ systems [4,20]. The presence of hydatid cysts in the pelvic and abdominal organs in some reported cases of urinary bladder hydatid cysts supports direct extension as a cause of urinary bladder hydatid cysts [15,18, 19].

The first reported case of urinary hydatid cyst belongs to 1894 in Germany when Dr.Harlan was called to see and assess a 51-year-old woman who presented with severe right hypochondrial pain and dyspnea for two days. She reported having the same complaint for three years but in a milder form. Later she was found to have hydatid cysts in the liver, pleura, omentum, mesentery, and urinary bladder [18].

This was followed by the report of Vaidyanathan et al. who presented two females one 10 other 50 years old in 1979 in India. Both patients presented with suprapubic pain with hematuria. They also had grape-like clusters in the urine. They were managed conservatively with Intra-cystic administration of 20% saline for about 30 minutes followed by bladder wash with sterile water for seven days and transfusion of blood [19].

The most recent report regarding bladder hydatid cyst has just been published by Malakzai et al. from Afghanistan. In their

study, they described a middle age male presented with lower abdominal pain and urinary retention. Abdominal sonography revealed a septated cystic lesion, provisionally he was diagnosed as a case of transitional carcinoma of the bladder. A computed tomography scan (CT scan) showed a mass without significant signs of a hydatid cyst. The patient was managed as a cancer later it was proven to be a bladder hydatid cyst [17].

## 5. Conclusion

Bladder hydatid cyst is a rare condition with a few reported cases. It presents a diagnostic challenge to the physician. Surgical intervention is the best management option.

## Declarations

**Conflicts of interest:** The author(s) have no conflicts of interest to disclose.

**Ethical approval:** Not applicable, as reviews do not require ethical approval.

**Patient consent** (participation and publication): Not applicable.

**Funding:** The present study received no financial support.

**Acknowledgements:** None to be declared.

**Authors' contributions:** RAH Participated in data collection, Literature review and critical revision of the manuscript; FA major contribution to the idea, data analysis, manuscript writing and final approval of the manuscript; BTS Participated in data collection, Literature review and critical revision of the manuscript. All authors approved the final version of the manuscript.

**Data availability statement:** Note applicable.

## References

1. Abebe Tesfaye Gessese. Review on Epidemiology and Public Health Significance of Hydatidosis. *Veterinary Medicine International*. 2020; 1: 1-8. [doi:10.1155/2020/8859116](https://doi.org/10.1155/2020/8859116)
2. Salih, A. M., Kakamad, F., Hammood, Z. D., Yasin, B., Ahmed, D. M. Abdominal wall Hydatid cyst: A review a literature with a case report. *International Journal of Surgery Case Reports*. 2017; 37: 154-156. [doi:10.1016/j.ijscr.2017.06.022](https://doi.org/10.1016/j.ijscr.2017.06.022)
3. Casulli, A., Massolo, A., Saarna, U. Gérald Umhang, Federica Santolamazza, Azzurra Santoro. Species and genotypes belonging to *Echinococcus granulosus sensu lato* complex causing human cystic echinococcosis in Europe (2000–2021): a systematic review. *Parasites Vectors*. 2022; 15, 109. [doi:10.1186/s13071-022-05197-8](https://doi.org/10.1186/s13071-022-05197-8)
4. Salih, A. M., Kakamad, F., Rauf, G. M. Isolated hydatid cyst of the diaphragm, a case report. *International Journal of Surgery Case Reports*. 2016; 29, 130-132. [doi:10.1016/j.ijscr.2016.10.071](https://doi.org/10.1016/j.ijscr.2016.10.071)
5. Pourseif, M. M., Moghaddam, G., Nematollahi, A., Khordadmehr, M., Naghili, B., Dehghani, J., et al. Vaccination with rEGVac elicits immunoprotection against different stages of *Echinococcus granulosus* life cycle: A pilot study. *Acta Tropica*. 2021; 218, 105883. [doi:10.1016/j.actatropica.2021.105883](https://doi.org/10.1016/j.actatropica.2021.105883)
6. Baram A, Kakamad FH, Alwan AA. Primary posterior mediastinal hydatid cyst mimicking malignant mediastinal neurogenic tumor. *International Journal of Case Reports and Images* 2014;5(1):54–57. [doi:10.5348/ijcri-2014-01-439-cr-12](https://doi.org/10.5348/ijcri-2014-01-439-cr-12)
7. Fadel, S.A., Asmar, K., Faraj, W. Mohammad Khalife, Maurice Haddad, Fadi El-Merhi. Clinical review of liver hydatid disease and its unusual presentations in developing countries. *Abdom Radiol*. 2018; 44, 1331–1339. [doi:10.1007/s00261-018-1794-7](https://doi.org/10.1007/s00261-018-1794-7)
8. Salih, A. M., Ahmed, D. M., Kakamad, F. H., Essa, R. A., Hunar, A., Ali, H. M. Primary chest wall Hydatid cyst: Review of literature with report of a new case. *International Journal of Surgery Case Reports*. 2017;41, 404-406. [doi:10.1016/j.ijscr.2017.10.051](https://doi.org/10.1016/j.ijscr.2017.10.051)
9. Abdulhameed MF, Habib I, Al-Azizz SA, Robertson I. Cystic echinococcosis in marketed offal of sheep in Basrah, Iraq: Abattoir-based survey and a probabilistic model estimation of the direct economic losses due to hydatid cyst. *Parasite Epidemiol Control*. 2018;3(1):43-51. [doi:10.1016/j.parepi.2018.02.002](https://doi.org/10.1016/j.parepi.2018.02.002)
10. Salih, A. M., Abdulla, Z. Y., Mohammed, D. A., Jwamer, V. I., Ali, P. G., Hamasaeed, A. G., et al. Hydatid cyst of thyroid gland, a rare case report with a literature review. *International Journal of Surgery Case Reports*. 2020; 67: 267-270. [doi:10.1016/j.ijscr.2020.02.019](https://doi.org/10.1016/j.ijscr.2020.02.019)
11. sardar Hassan arif, ayad ahmad Mohammed. Primary hydatid cyst of the urinary bladder. *BMJ Case Rep*. 2018; 7:1-3. [doi:10.1016/j.crwh.2021.e00330](https://doi.org/10.1016/j.crwh.2021.e00330)
12. Mustafa HM, Muhammad NH, Kakamad FH, Essa RA, Rahem HM. Hydatid disease causing paraplegia: A case report with literature review. *Edorium J Infect Dis*. 2017;3:17–20. [doi:10.0008i03hm2017](https://doi.org/10.0008i03hm2017)
13. Kakamad F, Abdullah H, Mohammed S, Abdalla B, Rahim H, Hassan M, et al. Kscien's List; A New Strategy to Discourage Predatory Journals and Publishers (Second Version) . *Barw Medical Journal*. 2023;1(1). [doi:10.58742/BMJ.V1I1.14](https://doi.org/10.58742/BMJ.V1I1.14)
14. Arif sH, Mohammed aa. Primary hydatid cyst of the urinary bladder *BMJ case report*. 2018;DOI: [doi:10.1136/bcr-2018-226341](https://doi.org/10.1136/bcr-2018-226341)
15. F. A. Ganie, O. H. Dar, A. Kaleem, S. Hassan, M. Gani. Hydatid cyst of urinary bladder. *Indian Journal of Nephrology*. 2013;23(6):462-643. [doi:10.4103/0971-4065.120348](https://doi.org/10.4103/0971-4065.120348)
16. Deepa V. Kanagal · Lokeshchandra C. Hanumanalu. Hydatid cyst of urinary bladder associated with pregnancy: a case report. *Arch Gynecol Obstet* (2010) 282:29–32. [doi:10.1007/s00404-010-1393-5](https://doi.org/10.1007/s00404-010-1393-5)
17. Haider Ali Malakzai, Zekrullah Baset, Abdul Sami Ibrahimkhalil, Mehmood Shah Rahimi, Jamshaid Khan, Ahmed Nasir Hanif. Primary hydatid cyst of the urinary bladder with associated eosinophilic cystitis: Report of a unique case. *Urology Case Reports*. 2023;46: 102296. [doi:10.1016/j.eucr.2022.102296](https://doi.org/10.1016/j.eucr.2022.102296)
18. Harlam M. Page. A case of Echinococcus cysts of the liver, pleura, omentum, mesentery, peritoneum and bladder. *Medical Record*. 1894;48(12):1866-1922. DOI: N/A
19. S. Vaidyanathan, M.S. Rao, S. K. Sharma, L. J. Rajendran, C. L. Subuthi, K. M. K. Rao. Et al. Non-operative management of a pelvic hydatid cyst communicating with the bladder. *The journal of urology*. 1979;121:245-247. [doi:10.1016/s0022-5347\(17\)56736-1](https://doi.org/10.1016/s0022-5347(17)56736-1)
20. Mehta P, Prakash M, Khandelwal N. Radiological manifestations of hydatid disease and its complications. *Trop Parasitol*. 2016;6(2):103-112. [doi:10.4103/2229-5070.190812](https://doi.org/10.4103/2229-5070.190812)